

Coronary Angiography and Intravascular Ultrasound — Spatio-Temporal Modeling and Quantification by Data Fusion

Andreas Wahle, Ph.D.

Department of Electrical and Computer Engineering
The University of Iowa, Iowa City, IA 52242–1527, U.S.A.

Abstract

The accurate representation of vessel geometry and plaque morphology is an important factor in the assessment of coronary atherosclerosis. The two most frequently used imaging modalities in interventional cardiology are x-ray angiography and intravascular ultrasound (IVUS). Considered separately, each of these modalities has certain advantages and disadvantages. Combined, substantially more information is delivered since they complement each other. We have developed a comprehensive system for fusion of coronary image data from biplane angiography and IVUS, resulting in a 3-D or 4-D (3-D plus time) model of the vessel under consideration. This article gives a brief overview on the underlying methods and the clinical applications.

1 Introduction

In the analysis of coronary atherosclerosis, the knowledge about the vessel geometry and plaque morphology is of utmost importance. Selective coronary angiography has been the method of choice for decades [1]. There are inherent limitations of x-ray angiography however, which can only deliver information about the vessel lumen and is subject to distortions such as foreshortening. Analysis on the plaque distribution, e.g., for the purpose of quantifying the extent of diffuse atherosclerosis in a coronary artery [2,3], can only be done indirectly from the vessel lumen. Further, determination of the lumen shape may be ambiguous in small vessels such as coronaries if only the projected lumen profiles are available, even though comparable methods were shown effective in larger vessels and ventricles [4,5]. Intravascular ultrasound (IVUS) has evolved as a complementary imaging modality to obtain cross-sectional images of vessel wall and plaque [1,6–8]. The main drawback of the conventional way of creating 3-D IVUS datasets by a straight stacking of 2-D frames acquired during a slow pullback is an inaccurate representation of the vessel geometry. Combining the information on the vessel course delivered by biplane angiography with the cross-sectional data obtained from IVUS results in an optimum use of the available data towards an accurate 3-D model of the vessel [1,9–11]. This data fusion approach also can be performed by acquiring the image data over the entire heart cycle and afterwards sorting them into several heart phases, thus generating a 4-D (3-D plus time) dataset [12,13]. The flow chart in Fig. 1 shows the order of the different steps of preprocessing, fusion, and evaluation.

2 Methodology

The image acquisition process consists of two steps to obtain the input data required for the fusion process: (1) biplane angiographic imaging of the vessel filled with diluted contrast dye and the

IVUS catheter inserted to its distal endpoint; (2) continuous IVUS image acquisition of an up to 12 cm long vessel segment with 0.5 mm/s motorized pullback. The resulting dataset is split into phases based upon the ECG signal, thus forming multiple 3-D datasets of corresponding heart phases [13]. A detailed description of our fusion approach can be found in [9, 10]. Importantly, the angiograms depict the vessel outline and the prospective path of the IVUS transducer during pullback (Fig. 2a/b). These are used to map the IVUS frames into 3-D space. Pullback path and lumen outline can be reconstructed based upon some known parameters of the imaging geometry and known reference points within the images for refinement [2, 14]. The IVUS frames, an example of which is shown in Fig. 2c, are segmented for lumen/plaque and media/adventitia borders, their 3-D locations along the pullback path identified by their timestamps, and their 3-D orientations determined by a statistical approach finding the best fit of the IVUS frame set with respect to the 3-D angiographic lumen outline. All phases combined, the 4-D model describes two moving tubular surfaces, which can be used to define finite-element meshes for the vessel wall, including accumulated plaque, and the lumen. As best suitable for the following evaluation steps, the lumen is represented as an unstructured tetrahedral mesh (Fig. 2d) to model arbitrarily shaped volumina by homogeneously sized elements, and the vessel wall is represented by a structured mesh with radial sectors and multiple layers (Fig. 3c). The use of ISO/IEC and industry standards, specifically DICOM[®] for input image data, XML to organize data flow, VRML for visualization, and Tecplot[®] for contour and mesh data, allows efficient data handling and exchange with evaluation and display tools.

3 Applications

There are many applications for which the model resulting from angio/IVUS fusion can be used. In addition to static or interactive 3-D and 4-D visualization techniques [13, 15], including virtual angioscopy (Fig. 2e), the quantification of new morphological and hemodynamic indices on a truly spatial model is of paramount interest. Local volumina of plaque and vessel lumen can be calculated in a geometrically correct model [16], thus obtaining a substantially higher accuracy as compared to conventional 2-D methods. The models can be used as input for algorithms of computational fluid dynamics (CFD), e.g., to estimate the local wall shear stress [13, 17, 18] and to verify common assumptions on the correlation between wall shear stress, plaque thickness, and curvature [19]. Further, the fusion method can be used to evaluate the results of interventional procedures, e.g., brachytherapy. Intravascular brachytherapy is a method to reduce the probability of recurrent in-stent restenosis, where the underlying dosing model assumes optimum conditions. However, as shown in Fig. 3, conventional assumptions of a centered delivery catheter cannot be assured in practice. By locating the beta-radiation sources and approximating the accumulated doses in a grid of points in the irradiated vessel segments, inaccuracies in the dose prescription and problems in the design of the brachytherapy catheters can be identified [20].

4 Results and Conclusions

In this ongoing study, we have thus far acquired data from 36 routine patients, 11 of which underwent intravascular brachytherapy, and 2 were heart-transplant patients. The results to date are showing (1) that the fusion approach can be used to create models suitable for computational hemodynamic studies [13], (2) that there is a dependency between vessel curvature and circumferential plaque distribution [19], and (3) that geometrically correct brachytherapy models show a higher variance in dose as compared to conventional models [20]. In summary, data fusion from biplane

angiography and intravascular ultrasound opens new perspectives on studying the development of plaque in the process of coronary atherosclerosis, and allows a better assessment of the results from interventional procedures than either modality alone can deliver.

Acknowledgments

The author would like to thank the National Institutes of Health for their financial support (grant R01 HL63373); the principal investigator in this project, Dr. Milan Sonka (Department of Electrical & Computer Engineering); the co-investigators Krishnan B. Chandran (Biomedical Engineering); Yong-Gen Lai (IIHR - Hydrosience and Engineering); James D. Rossen, Theresa M. H. Brennan, Kathleen C. Braddy, and James M. Fox (Internal Medicine/Cardiology); John M. Buatti, Sanford L. Meeks, and Edward C. Pennington (Radiation Oncology); our collaborators John J. Lopez (University of Chicago); Rubén Medina (Universidad de Los Andes, Venezuela); Clemens von Birgelen (University Hospital Essen, Germany); Peter H. Stone and Charles L. Feldman (Brigham & Women's Hospital, Boston); Johan H. C. Reiber (Leiden University Medical Center, Netherlands); as well as all students and staff involved.

References

- [1] J. H. C. Reiber, G. Koning, J. Dijkstra, A. Wahle, B. Goedhart, F. H. Sheehan, and M. Sonka. Angiography and intravascular ultrasound. In M. Sonka and J. M. Fitzpatrick, editors, *Handbook of Medical Imaging — Volume 2: Medical Image Processing and Analysis*, pages 711–808, Bellingham WA, 2000. SPIE Press.
- [2] A. Wahle, E. Wellnhofer, I. Mugaragu, H. U. Sauer, H. Oswald, and E. Fleck. Assessment of diffuse coronary artery disease by quantitative analysis of coronary morphology based upon 3-D reconstruction from biplane angiograms. *IEEE Transactions on Medical Imaging*, 14(2):230–241, June 1995.
- [3] E. Wellnhofer, A. Wahle, and E. Fleck. Progression of coronary atherosclerosis quantified by analysis of 3-D reconstruction of left coronary arteries. *Atherosclerosis*, 160(2):483–493, February 2002.
- [4] G. P. M. Prause and D. G. W. Onnasch. Binary reconstruction of the heart chambers from biplane angiographic image sequences. *IEEE Transactions on Medical Imaging*, 15(4):532–546, August 1996.
- [5] K. R. Hoffmann, A. Wahle, C. Pellot-Barakat, J. Sklansky, and M. Sonka. Biplane X-ray angiograms, intravascular ultrasound, and 3-D visualization of coronary vessels. *International Journal of Cardiac Imaging*, 15(6):495–512, December 1999.
- [6] C. von Birgelen, E. A. de Vrey, G. S. Mintz, A. Nicosia, N. Bruining, W. Li, C. J. Slager, J. R. T. C. Roelandt, P. W. Serruys, and P. J. de Feyter. ECG-gated three-dimensional intravascular ultrasound: Feasibility and reproducibility of the automated analysis of coronary lumen and atherosclerotic plaque dimensions in humans. *Circulation*, 96(9):2944–2952, November 1997.
- [7] X. Zhang, C. R. McKay, and M. Sonka. Tissue characterization in intravascular ultrasound images. *IEEE Transactions on Medical Imaging*, 17(6):889–899, December 1998.
- [8] E. G. P. Bovenkamp, J. Dijkstra, J. G. Bosch, and J. H. C. Reiber. Multi-agent IVUS image interpretation. In M. Sonka and J. M. Fitzpatrick, editors, *Medical Imaging 2003: Image Processing*, volume 5032, Bellingham WA, 2003. SPIE Proceedings. (in press).
- [9] A. Wahle, G. P. M. Prause, S. C. DeJong, and M. Sonka. Geometrically correct 3-D reconstruction of intravascular ultrasound images by fusion with biplane angiography — methods and validation. *IEEE Transactions on Medical Imaging*, 18(8):686–699, August 1999.
- [10] A. Wahle, G. P. M. Prause, C. von Birgelen, R. Erbel, and M. Sonka. Fusion of angiography and intravascular ultrasound in-vivo: Establishing the absolute 3-D frame orientation. *IEEE Transactions on Biomedical Engineering*, 46(10):1176–1180, October 1999.
- [11] C. J. Slager, J. J. Wentzel, J. C. H. Schuurbijs, J. A. F. Oomen, J. Kloet, R. Krams, C. von Birgelen, W. J. van der Giessen, P. W. Serruys, and P. J. de Feyter. True 3-dimensional reconstruction of coronary arteries in patients by fusion of angiography and IVUS (ANGUS) and its quantitative validation. *Circulation*, 102(5):511–516, August 2000.
- [12] N. Bruining, C. von Birgelen, M. T. Mallus, P. J. de Feyter, E. de Vrey, W. Li, F. Prati, P. W. Serruys, and J. R. T. C. Roelandt. ECG-gated ICUS image acquisition combined with a semi-automated contour detection provides accurate analysis of vessel dimensions. In *Proc. Computers in Cardiology 1996*, pages 53–56, Piscataway NJ, 1996. IEEE Press.

- [13] A. Wahle, S. C. Mitchell, S. D. Ramaswamy, K. B. Chandran, and M. Sonka. Four-dimensional coronary morphology and computational hemodynamics. In M. Sonka and K. M. Hanson, editors, *Medical Imaging 2001: Image Processing*, volume 4322, pages 743–754, Bellingham WA, 2001. SPIE Proceedings.
- [14] S. Y. J. Chen and C. E. Metz. Improved determination of biplane imaging geometry from two projection images and its application to three-dimensional reconstruction of coronary arterial trees. *Medical Physics*, 24(5):633–654, May 1997.
- [15] A. Wahle, S. C. Mitchell, S. D. Ramaswamy, K. B. Chandran, and M. Sonka. Virtual angiography in human coronary arteries with visualization of computational hemodynamics. In C. Chen and A. V. Clough, editors, *Medical Imaging 2001: Physiology and Function from Multidimensional Images*, volume 4321, pages 32–43, Bellingham WA, 2001. SPIE Proceedings.
- [16] R. Medina, A. Wahle, M. E. Olszewski, and M. Sonka. Three methods for accurate quantification of plaque volume in coronary arteries. *International Journal of Cardiovascular Imaging*, 2003. (in press).
- [17] R. Krams, J. J. Wentzel, J. A. F. Oomen, R. Vinke, J. C. H. Schuurbiers, P. J. de Feyter, P. W. Serruys, and C. J. Slager. Evaluation of endothelial shear stress and 3-D geometry as factors determining the development of atherosclerosis and remodeling in human coronary arteries in-vivo; combining 3-D reconstruction from angiography and IVUS (ANGUS) with computational fluid dynamics. *Arteriosclerosis, Thrombosis and Vascular Biology*, 17(10):2061–2065, October 1997.
- [18] P. H. Stone, A. U. Coşkun, S. Kinlay, M. E. Clark, M. Sonka, A. Wahle, O. J. Ilegbusi, J. J. Popma, R. E. Kuntz, and C. L. Feldman. Prediction of sites of progression of native coronary disease in-vivo based on identification of sites of low endothelial shear stress. *American College of Cardiology, 51st Scientific Sessions — Journal of the ACC (Supplement)*, 39(5/A), March 2002. Abstract 1056-82.
- [19] A. Wahle, R. Medina, K. C. Braddy, J. M. Fox, T. M. H. Brennan, J. J. Lopez, J. D. Rossen, and M. Sonka. Impact of local vessel curvature on the circumferential plaque distribution in coronary arteries. In A. V. Clough and A. A. Amini, editors, *Medical Imaging 2003: Physiology and Function: Methods, Systems, and Applications*, volume 5031, Bellingham WA, 2003. SPIE Proceedings. (in press).
- [20] A. Wahle, J. J. Lopez, E. C. Pennington, S. L. Meeks, K. C. Braddy, J. M. Fox, T. M. H. Brennan, J. M. Buatti, J. D. Rossen, and M. Sonka. Effects of vessel geometry and catheter position on dose delivery in intracoronary brachytherapy. *IEEE Transactions on Biomedical Engineering*, 2003. (in press).

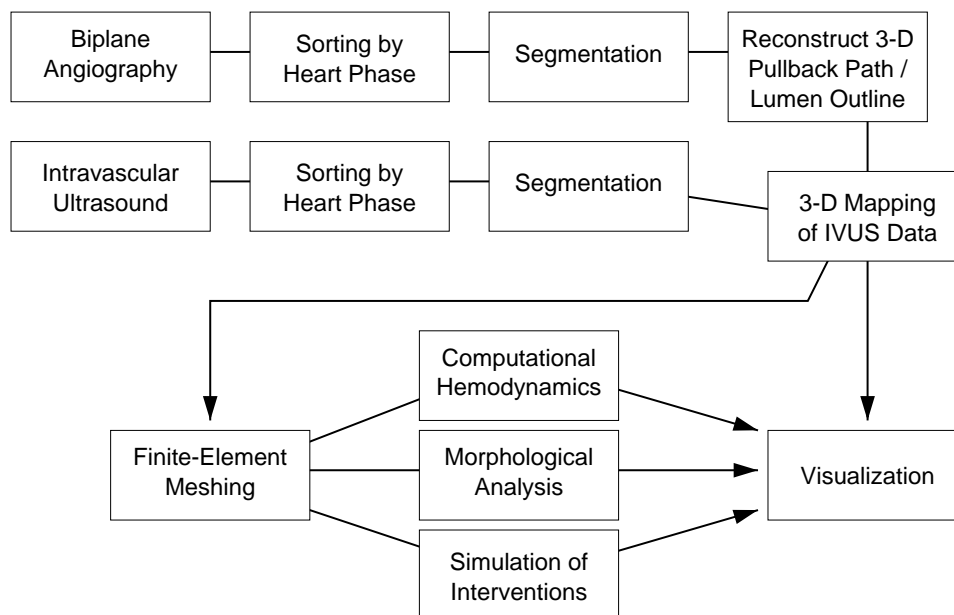


Figure 1: Flowchart of the fusion process: Acquisition of angiographic and IVUS data (top, left to right), followed by evaluation of the resulting model and visualization (bottom).

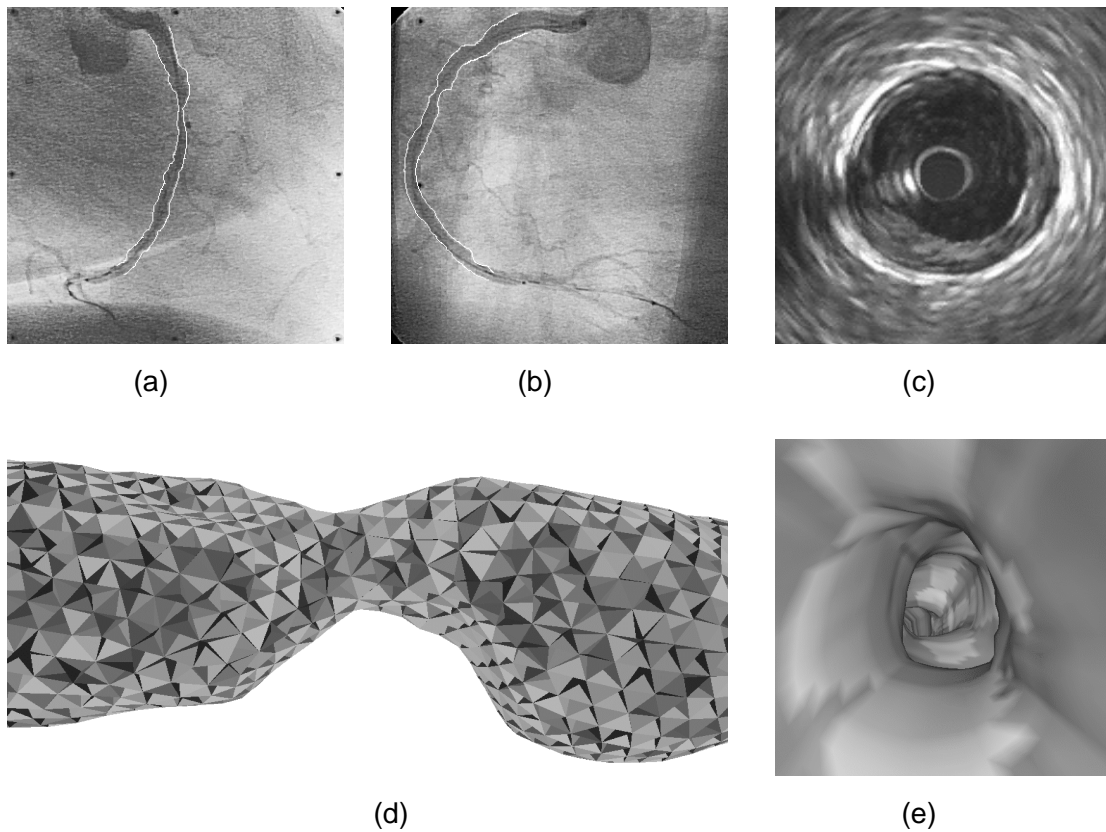


Figure 2: Fusion process and grid generation on in-vivo patient data: (a) right and (b) left anterior oblique projections of a stenosed right coronary artery before treatment, with the IVUS catheter depicted as a black line within the white lumen borders; (c) IVUS image approx. 1 cm distal from the most stenotic location showing the catheter itself in the center, the lumen, plaque, a narrow black ring representing the media, and the adventitia; (d) after segmentation and 3-D fusion, the volume enclosed by the lumen surface is filled with a tetrahedral unstructured mesh for CFD analysis; (e) endoscopic view within the vessel lumen from the position of (c) towards the stenosis.

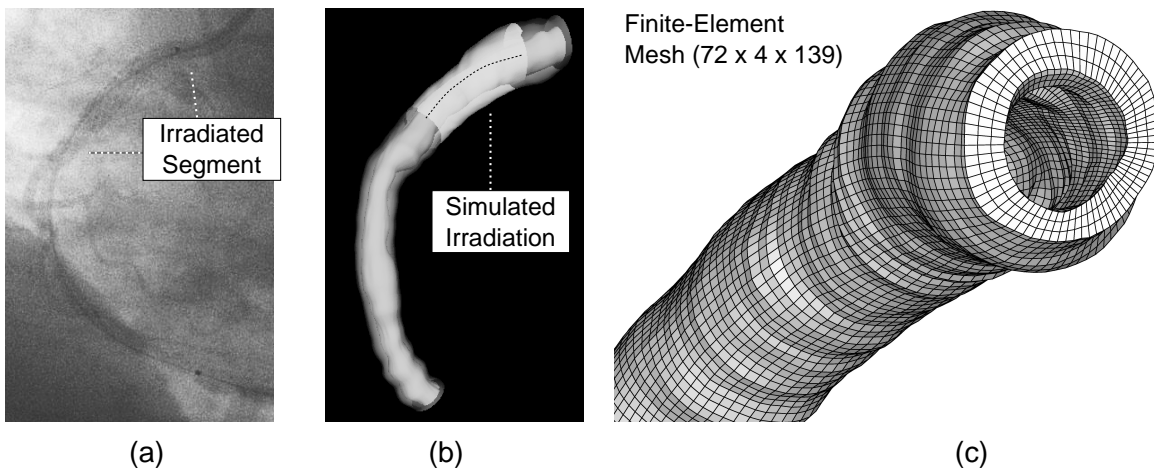


Figure 3: Simulation of the intravascular brachytherapy treatment: (a) right coronary artery with in-stent restenosis after treatment; (b) 3-D model of the lumen/plaque and media/adventitia interfaces, with the irradiated segment and the simulated source train included; (c) finite-element mesh used to estimate the dose delivered in each intersection point.